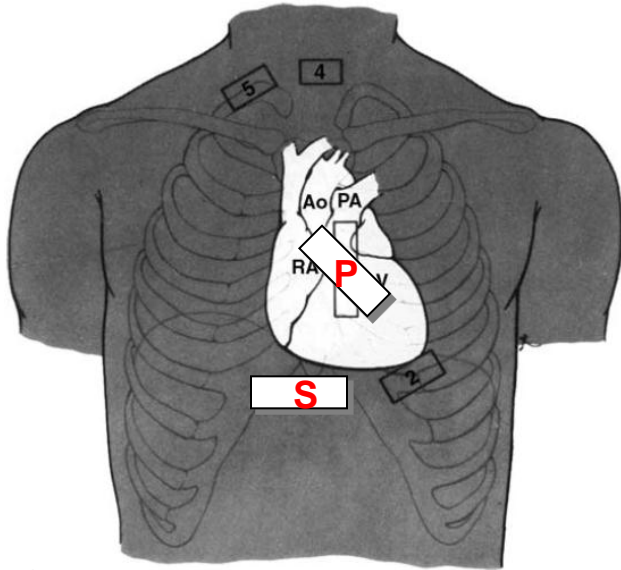


# Bedside Ultrasound for CHF

www.SinaiEM.us



## Common cardiac probe positions

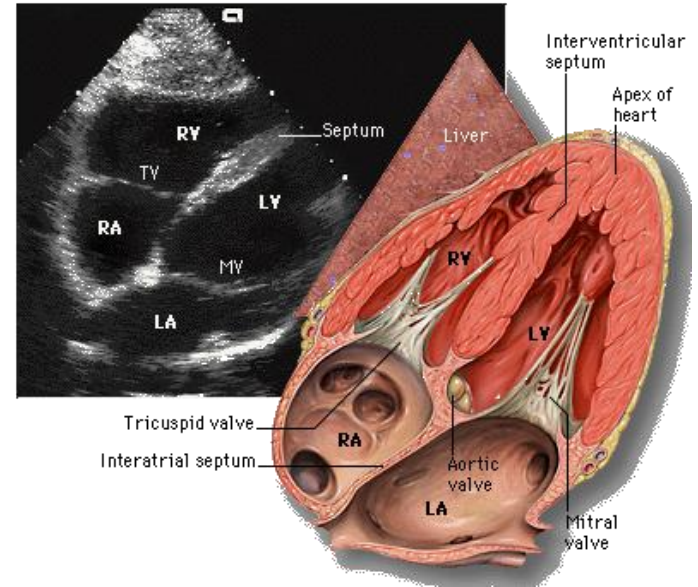
### (S) Subxiphoid view:

- Cardiac preset
- Probe marker to patient Right
- Point probe toward Left shoulder
- View all 4 chambers

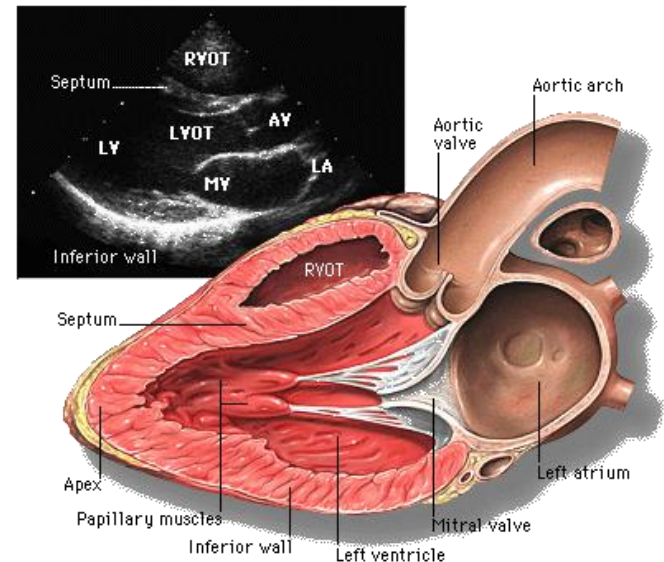
### (P) Parasternal Long Axis view:

- Cardiac preset
- Probe marker to patient's Right shoulder
- Point probe straight down into chest
- View left ventricle, Apex, Mitral Valve, Aortic Valve

## Subxiphoid view

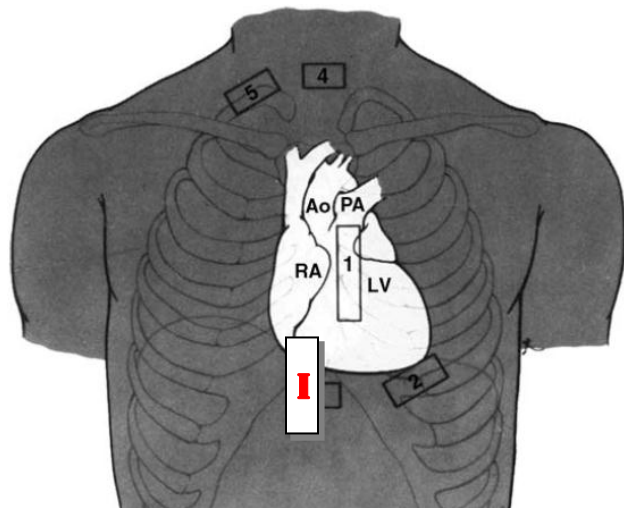


## Parasternal view

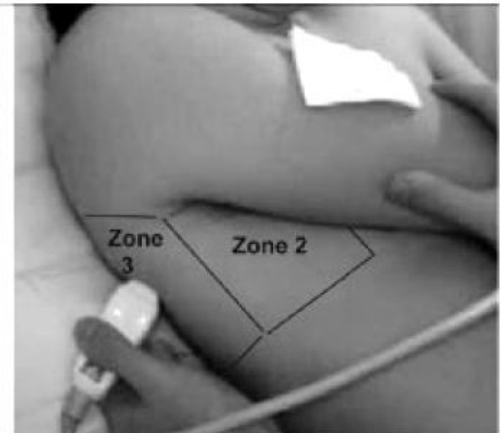
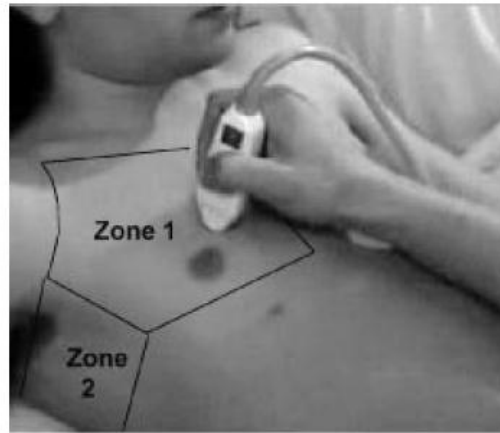


Anatomy images from: Yale Online Echocardiography Atlas

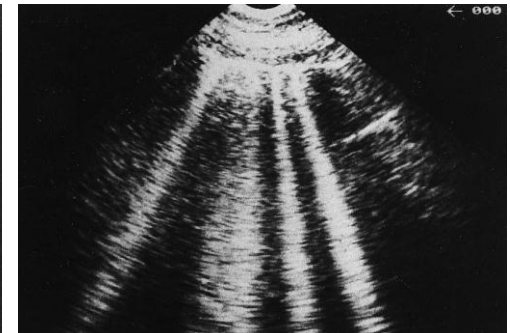
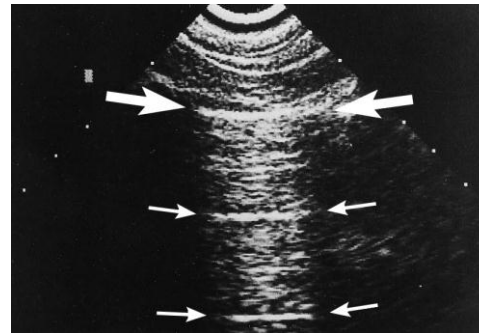
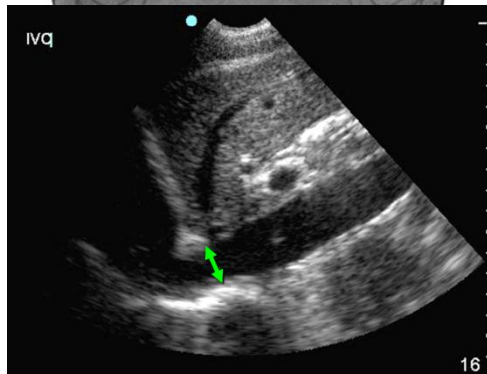
# IVC view



# Thorax views

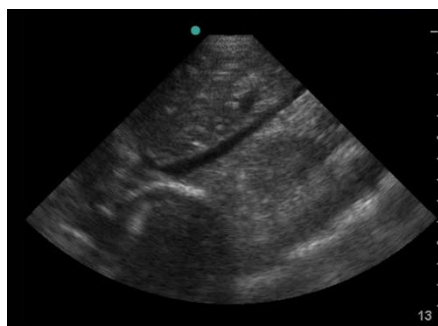


Abdomen preset, marker towards patient's head

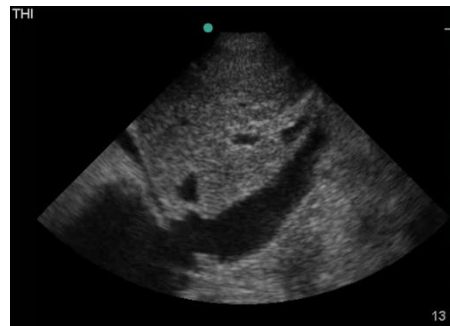

A-Lines- no edema

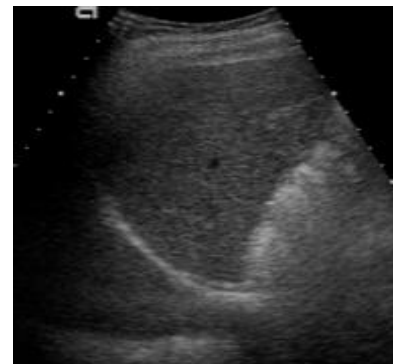B-Lines- pulmonary edema



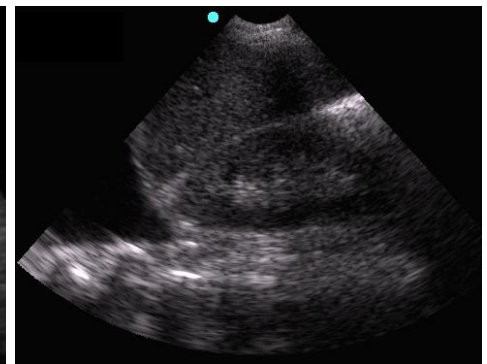
Flat IVC



Plethoric IVC



Normal diaphragm



Pleural effusion