

# Trauma Ultrasound

Phillip Andrus, MD, FACEP  
Mount Sinai School of Medicine  
Division of Emergency Ultrasound  
New York, NY  
March 8, 2010

There are many applications of sonography in trauma. The FAST and now eFAST exams are the most well known. Increasing familiarity with ocular and musculoskeletal ultrasound has provided new tools to traumatologists. Undoubtedly, not yet imagined uses of ultrasound in trauma remain to be uncovered. Today we will cover the eFAST exam and ocular ultrasound in trauma.

---

## eFAST Exam

The eFAST (Extended Focused Assessment with Sonography in Trauma) is used to detect sequelae of trauma not evident on physical exam. It is the latest evolution of a long history of use of ultrasound in trauma patients. Initially used in Europe in the 1970s, trauma ultrasound has replaced the use of DPL in most US Centers, and is required as part of ATLS and Emergency Medicine resident training. Essentially, the exam is a methodical search for hypoechoic free fluid (blood) in the dependent regions of the abdomen, in the pericardial space and the thorax. When the FAST became the eFAST, the exam was Extended to include search for pneumothorax.

## Focused Questions











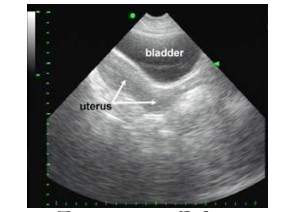
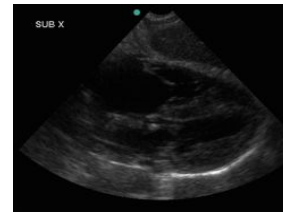



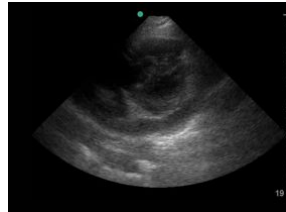

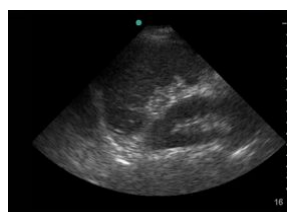

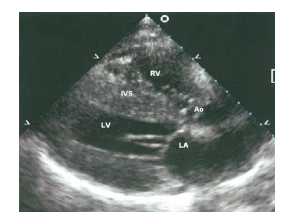
As with any emergency ultrasound application, this is not a comprehensive exam, but one designed to answer very focused questions. Specifically:

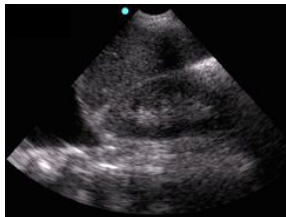

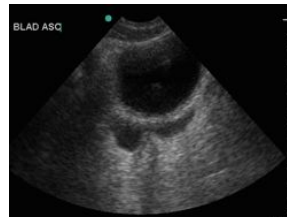

1. Is there free fluid in any of the following cavities?
  - Abdomen
  - Pericardium
  - Thorax
2. Is there pneumothorax?

# Scanning Technique


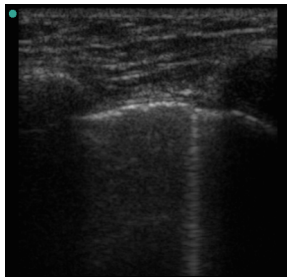
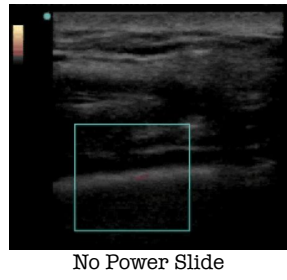
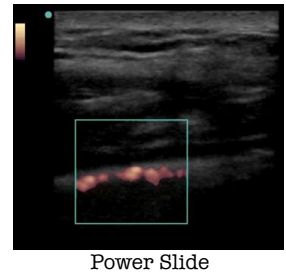
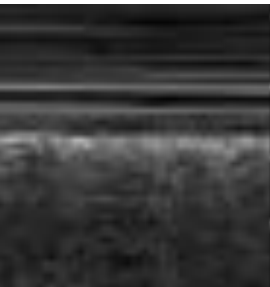
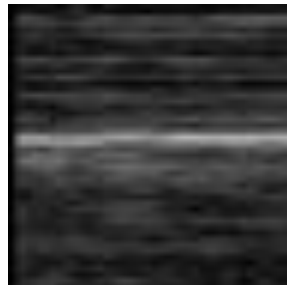
1. Use a curvilinear or phased array probe (2.5-5 MHz).
  - a. Larger footprint probes provide greater resolution of deep structures
  - b. Smaller footprint probes allow imaging between ribs
  - c. Can use these probes for pneumothorax evaluation or switch to a linear probe.
  
2. Positioning
  - a. Blood/Free Fluid is not immune to the laws of gravity. In supine trauma patients, the right paracolic gutter is the most dependent region in the abdomen, and the area where blood is most likely to collect. Positioning these patients in **Trendelenburg** shifts the areas of dependency and improves sensitivity of perihepatic and perisplenic exams
  - b. Consider **reverse Trendelenburg** for pelvic view.
  
3. Search for Free Fluid
  - a. **Perihepatic**: anterior axillary line 7th-9th intercostal space. Be sure to visualize the inferior pole of the kidney. Slide probe cephalad to costophrenic angle and look for loss of mirror imaging suggesting hemothorax.
  - b. **Perisplenic**: posterior axillary line 5th-7th intercostal space. Examine costophrenic angle for hemothorax
  - c. **Pelvic**: 2 cm superior to Pubis. Obtain Transverse and Longitudinal views. Be sure to visualize space posterior to bladder.
  - d. **Pericardial**: place probe subxyphoid nearly parallel to stretcher aimed at patient's left shoulder. Be sure to maximize depth to obtain the four chamber view of heart searching for pericardial effusion.
  
4. Search for Pneumothorax
  - a. **Normal**: lung sliding, power slide, comet tail artifacts, "waves on beach"
  - b. **Abnormal**: "stratosphere" sign, "barcode" sign, lung point.
  - c. Begin at second intercostal space -> slide down through all intercostal spaces.
  - d. Record images of dynamic scan as:
    - i. Video Clip
    - ii. Power Slide
    - iii. M-Mode

# FAST Views

Perihepatic	Perisplenic	Pelvic	Pericardial
 Sagittal	 Sagittal	 Transverse	 Subxyphoid
 Oblique	 Oblique	 Longitudinal	 Parasternal Long
 Normal Perihepatic	 Normal Perisplenic	 Transverse Pelvis	 Normal Subxyphoid
 Perihepatic Fluid	 Perisplenic Fluid	 Sagittal Pelvis	 Subxyphoid Pericardial Effusion
 R. Costophrenic Mirroring	 L. Costophrenic Mirroring	 Pelvic Fluid	 Normal Parasternal Long

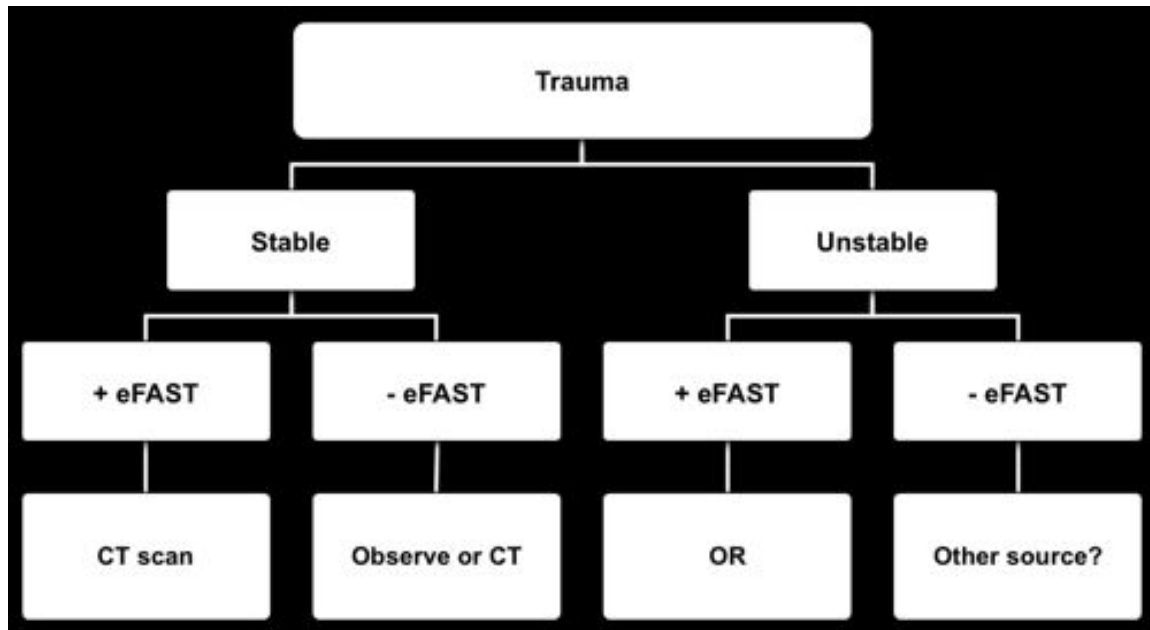
Perihepatic	Perisplenic	Pelvic	Pericardial
			
R. Hemothorax	L. Hemothorax	Pelvic Fluid	Parasternal Long Pericardial Effusion

## Thoracic Views for eFAST

Thoracic			
			
Pleura	Comet Tail	No Power Slide	Power Slide
			
M-Mode Seashore	M-Mode Stratosphere / Barcode		

## Algorithm

How do we use the results of our FAST exam? In no way does the FAST exam replace the much more sensitive computed tomography (CT) in trauma. It does provide very valuable information, however. One proposed algorithm integrating eFAST into trauma evaluation is diagrammed below. The eFAST should be repeated in any deteriorating patient or in patient's otherwise stable after a set period such as four hours.



# Ocular Exam

In trauma patients, ocular ultrasound has proven useful in the detection of intraocular trauma and in the noninvasive assessment of intracranial pressure (ICP). Elevated ICP in the trauma patient may expedite management with: medications such as mannitol or hypertonic saline, icp monitor placement, intracranial drains or operative intervention. Originally, optic nerve sheath diameter (ONSD) > 5 mm was correlated with an ICP > 20 mmHg. Several studies since have studied this and resulted in thresholds of 5.6 mm 5.8 mm. As a result, it appears that an ONSD measurement:

- <5mm unlikely elevated ICP
- 5-6 indeterminate - possible elevated ICP
- >6mm likely elevated ICP

## Focused Questions

1. Is there possible increased ICP (ONSD >5 mm)
2. Is there any other obvious ocular pathology?

## Contraindications

1. Open ocular trauma
2. Suspected globe rupture
3. Periorbital wounds

# Scanning Technique

1. Use High Frequency Linear Probe (7-10 MHz)
2. Apply Tegaderm® to closed eye
3. Dispense copious amount of gel onto Tegaderm®
4. Rest palm of scanning hand on zygoma/infraorbital rim
5. Make contact between vertically oriented probe and ultrasound gel
6. Avoid undue pressure on globe
7. Acquire images in transverse and longitudinal planes
8. Scan through retina to identify hypoechoic nerve sheath
9. Document any suspected abnormal findings: retinal detachment, vitreous hemorrhage, foreign body, etc.
10. Document ONSD.
  - Measure 3mm down from globe.
  - Measure diameter of nerve at this level.
  - Repeat on opposite eye for average binocular measurement.

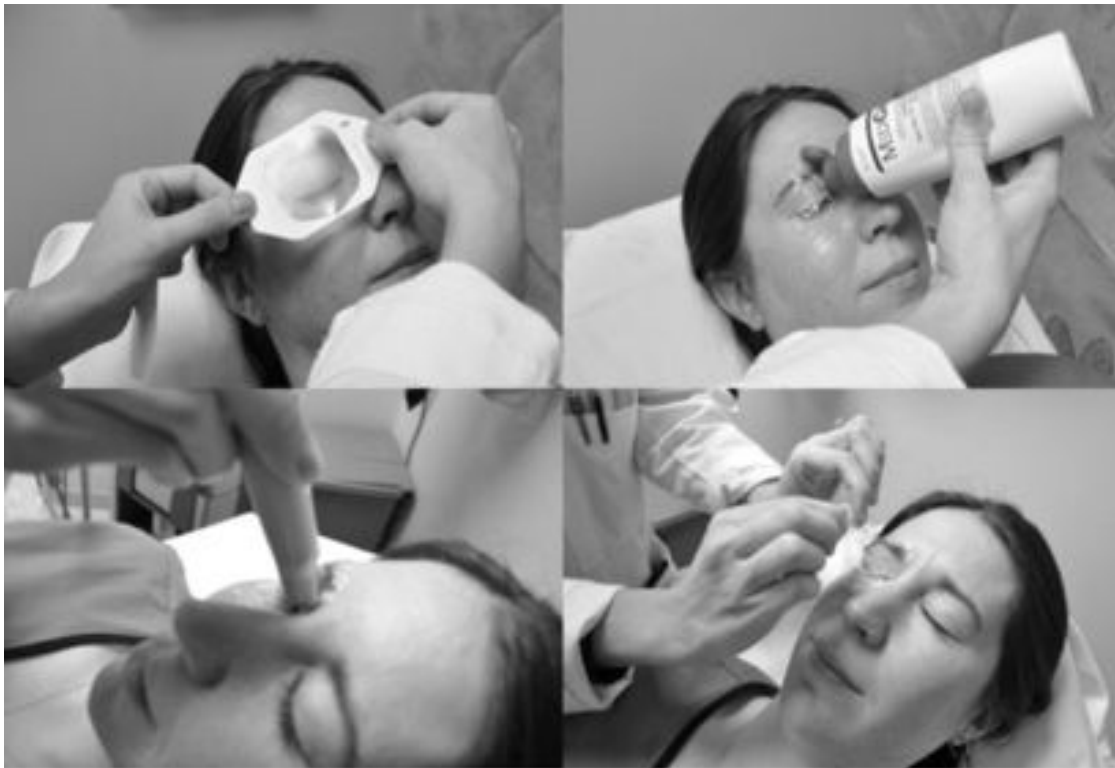

Image from: Roth JEM 2010

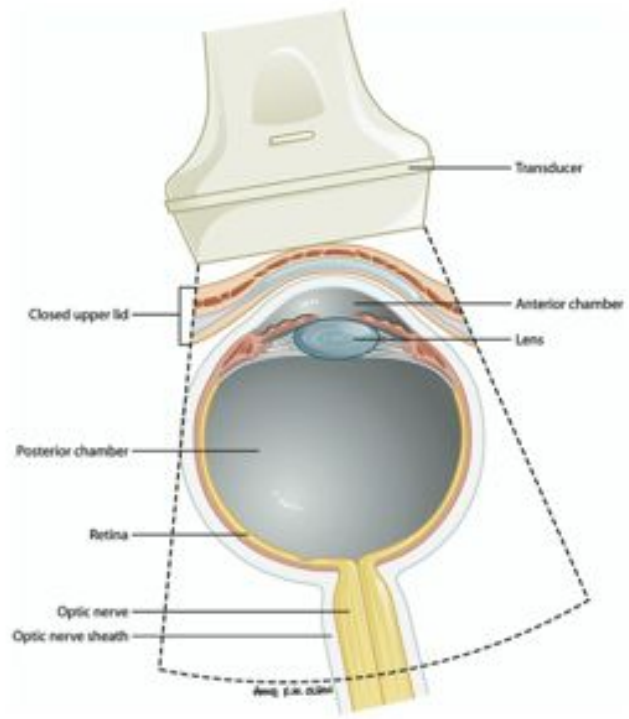
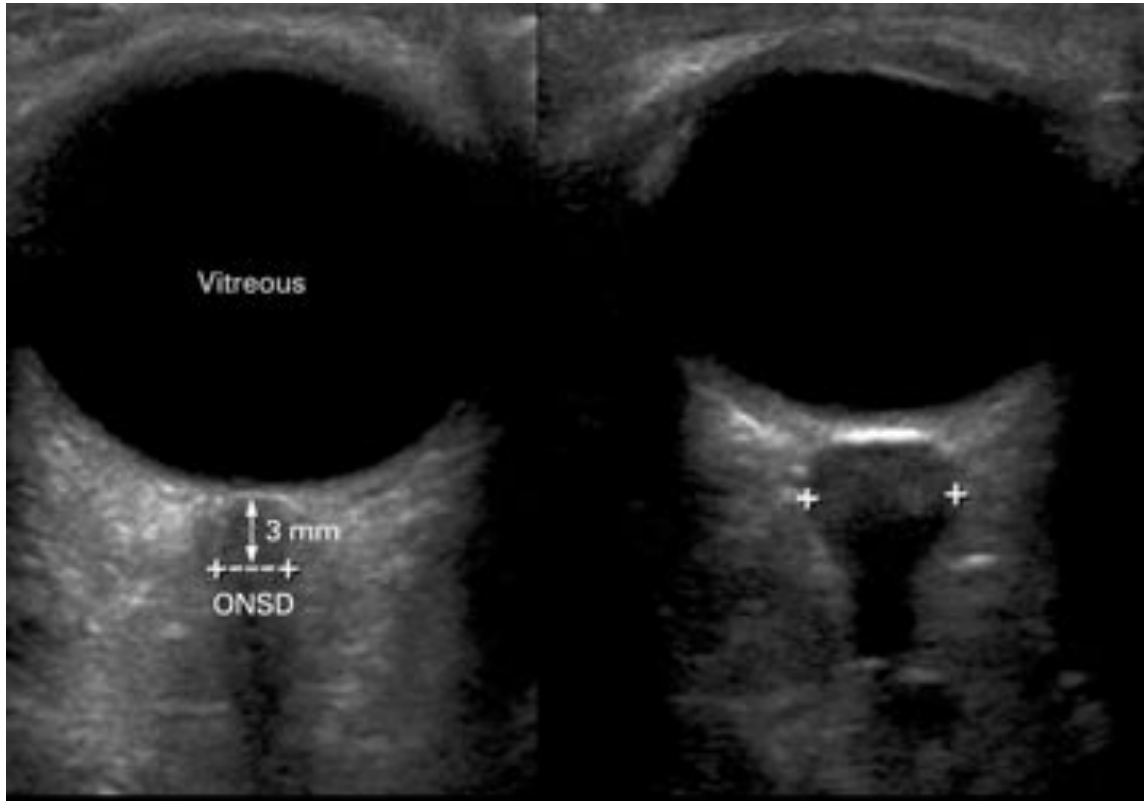


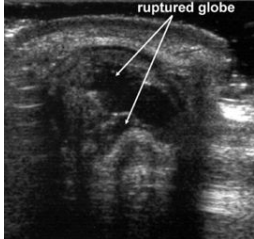

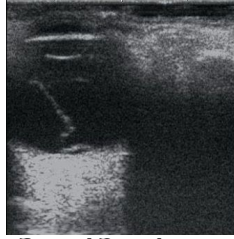
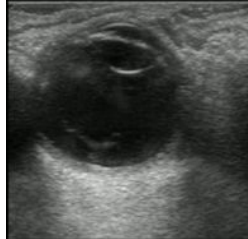
Image from: Tayal AEM 2007



normal

ONSD 8.11 mm

Image from: Soldatos EMJ 2009

Ocular Trauma			
 <p>Ruptured Globe</p>	 <p>Foreign Body</p>	 <p>Retinal Detachment</p>	 <p>Vitreous Hemorrhage</p>

# References

## FAST/eFAST

1. Heron MP, Hoyert DL, Murphy SL, Xu JQ, Kochanek KD, Tejada-Vera B. Deaths: Final data for 2006. National vital statistics reports; vol 57 no 14. Hyattsville, MD: National Center for Health Statistics. 2009.
2. Scalea TM, Rodriguez A, Chiu WC, Brenneman FD, Fallon WF Jr, Kato K, McKenney MG, Nerlich ML, Ochsner MG, Yoshii H. Focused Assessment with Sonography for Trauma (FAST): results from an international consensus conference. *J Trauma*,1999;46:466-72. Price D, Simon BC, Park RS. Evolution of emergency ultrasound. *California J Emerg Med*. 2003;4:82-88.
3. Kirkpatrick AW, Sirois M, Laupland KB, Liu D, Rowan K, Ball CG, Hameed SM, Brown R, Simons R, Dulchavsky SA, Hamilton DR, Nicolaou S. Hand-held thoracic sonography for detecting post-traumatic pneumothoraces: the Extended Focused Assessment with Sonography for Trauma (EFAST). *J Trauma*,2004;57:288-95.
4. Lichtenstein D, Meziere G, Lascols N, Biderman P, Courret JP, Gepner A, Goldstein I, Tenoudji-Cohen M. Ultrasound diagnosis of occult pneumothorax. *Crit Care Med*,2005;33:1231-8.
5. Ma OJ, Mateer JR, Ogata M, Kefer MP, Wittmann D, Aprahamian C. Prospective analysis of a rapid trauma ultrasound examination performed by emergency physicians. *J Trauma*, 1995;38:879-85.
6. Rozycki GS, Ochsner MG, Schmidt JA, Frankel HL, Davis TP, Wang D, Champion HR. A prospective study of surgeon-performed ultrasound as the primary adjuvant modality for injured patient assessment. *J Trauma*,1995;39:492-500.
7. Ma OJ, Mateer JR. Trauma ultrasound examination versus chest radiography in the detection of hemothorax. *Ann Emerg Med*, 1997;29:312-6.
8. Abrams BJ, Sukumvanich P, Seibel R, Moscato R, Jehle D. Ultrasound for the detection of intraperitoneal fluid: the role of Trendelenburg positioning. *Am J Emerg Med*,1999;17:117-20.
9. Reardon R, Ultrasound in Trauma - The FAST Exam. In sonoguide. Retrieved 3/1/2010, from <http://sonoguide.com/FAST.html>.
10. V. Noble, B. Nelson and A.N. Sutingco, Focused Assessment with Sonography in Trauma (FAST): Manual of emergency and critical care ultrasound (1<sup>st</sup> edn), Cambridge University Press, New York (2007).

## Ocular Ultrasound

1. T Soldatos, K Chatzimichail, M Papathanasiou, et al. Optic nerve sonography: a new window for the non-invasive evaluation of intracranial pressure in brain injury. *Emerg Med J* 2009 26: 630-634.
2. Kevin R. Roth, Gregory Gafni-Pappas, Unique Method of Ocular Ultrasound Using Transparent Dressings, *The Journal of Emergency Medicine*, In Press, Corrected Proof, Available online 25 January 2010, ISSN 0736-4679, DOI: 10.1016/j.jemermed.2009.10.020.
3. Tayal VS, Neulander M, Norton HJ, Foster T, Saunders T, Blaivas M, Emergency Department Sonographic Measurement of Optic Nerve Sheath Diameter to Detect Findings of Increased Intracranial Pressure in Adult Head Injury Patients, *Annals of Emergency Medicine*, Volume 49, Issue 4, April 2007, Pages 508-514.
4. Blaivas M, Theodoro D, Sierzenski P. Elevated intracranial pressure detected by bedside emergency ultrasonography of the optic nerve sheath. *Acad Emerg Med.*2003;10:376-381.
5. Blaivas M. Bedside emergency department ultrasonography in the evaluation of ocular pathology. *Acad Emerg Med.*2000;7:947-950.
6. V. Noble, B. Nelson and A.N. Sutingco, *Ocular ultrasound: Manual of emergency and critical care ultrasound* (1<sup>st</sup> edn), Cambridge University Press, New York (2007).

---

## Images



1. Personal Collection
2. [sonoguide.com](http://sonoguide.com)
3. [trauma.org](http://trauma.org)
4. [flickr.com](http://flickr.com)
5. Visible Human Project

---

## Contact

Phillip Andrus, MD, FACEP  
Department of Emergency Medicine  
Division of Emergency Critical Care  
Division of Emergency Ultrasound  
1 Gustave L. Levy Place  
New York, NY 10024

email: [phillip.andrus@mssm.edu](mailto:phillip.andrus@mssm.edu)

web: [sinaiem.us](http://sinaiem.us)